

RESURFACING OF THE FIRST METATARSAL HEAD FOR THE TREATMENT OF HALLUX RIGIDUS: EVOLUTION OF IMPLANT DESIGN, REVIEW OF CLINICAL EXPERIENCE AND PRELIMINARY 5 YEAR RESULTS OF METATARSAL HEAD RESURFACING

MTP RESURFACING STUDY GROUP:

CARL T. HASSELMAN, MD
University of Pittsburgh Medical
Center
Pittsburgh, PA

NAOMI SHIELDS, MD
University of Kansas
Wichita, KS

BRIAN CARPENTER, DPM
University of North Texas Health
Science Center
Fort Worth, TX

THOMAS SAN GIOVANNI, MD
Florida International University
School of Medicine
Miami, FL

ABSTRACT

Treatment of advanced stages of Hallux Rigidus remains controversial. Many authors have advocated arthrodesis despite inherent disadvantages associated with the procedure. While joint fusion achieves reproducible pain control, the loss of mobility is not acceptable for many patients especially those with an active lifestyle or profession. Metatarsal head resurfacing has gained increased interest since its inception in 2004. The purpose of this report is to provide a review of the clinical experience gained over the course of 5 years, emphasize technical consideration for improved outcomes, and outline the evolution of design concepts in metatarsophalangeal arthroplasty and resurfacing. Clinical results at 2 to 5 years show remarkable patient acceptance and satisfaction. Pain relief and activity ratings support the concept of a mobility preserving treatment with HemiCAP[®] resurfacing. The implant screw fixation is a critical strong point in light of previous reports on loosening associated with other arthroplasty procedures.

Key Words: Hallux Rigidus, toe, arthrodesis, fusion, arthroplasty, MTP, HemiCAP[®] resurfacing

Level of Evidence: Review

Introduction

Hallux rigidus is the most common area of arthritis in the foot and affects 1/40 patients older than 50 years (1). Management of the early disease stage is straight forward and involves conservative measures such as footwear modification or surgical treatment with cheilectomy. Surgical options for advanced stages of Hallux Rigidus remain controversial with many reports favouring arthrodesis despite the clinical shortcomings of this procedure. Joint fusion provides reproducible pain control at the cost of joint mobility. While fusion is only accepted as a salvage procedure of the last resort in other joints, arthrodesis of the metatarso-phalangeal joint (MPJ) has been widely publicized in part due to the mixed results of surgical alternatives like phalangeal based hemi-arthroplasty or total joint replacement (2-5)

In contrast to fusion promoting reports, Cook et al. (6) published high patient satisfaction in their meta-analysis of first metatarsophalangeal joint implant arthroplasty in 3049 procedures with a mean 61.48 month follow-up: 85.7% patients were satisfied, which

increased to 94.5% when adjusting for lower quality studies with less than 5 years follow-up. At the time of their publication, detailed results from HemiCAP[®] resurfacing (Arthrosurface, Franklin, MA) were pending, therefore the analysis was focused on first, second, and third generation of MTP implants with stemmed or keeled designs. With the availability of the Arthrosurface threaded screw fixation and modular surface components, a fourth generation implant was introduced to the market. The latest development comes in response to previously reported failure modes that centered on implant loosening in earlier implant designs (7-10).

First Evolution of HemiCAP[®] MTP Resurfacing

The majority of patients presenting to clinic with Hallux Rigidus have various degrees of cartilage defects involving primarily the metatarsal head. In order to address pain, preserve the joint, and improve the limitations in range of motion associated with the pathology, metatarsal head resurfacing was introduced in 2004 (11). The system allows for a modular approach using two different diameters of surface components, each with a variety of surface curvatures to match the patient's anatomy while restoring the native geometry of the joint. It consists of 2 components: A titanium tapered cannulated screw and a cobalt chrome articular component both fitted together via morse taper to provide a stable fixation in the metatarsal head (Figure 1).



Figure 1: First Evolution of HemiCAP[®] Metatarsal Head Resurfacing:

- High Pitched, Threaded Fixation
- Modular Articular Components in 12 and 15 mm diameter and various surface curvature offset sizes

Surgical Technique Summary

Using a dorsal incision, the joint is exposed and the extent of cartilage loss is assessed. After the appropriate size of the surface implant has been confirmed, a guide wire is introduced into the metatarsal head to provide a perpendicular (to the distal 1st metatarsal head) working axis for the cannulated implantation system. Fluoroscopy confirms the placement of the guide wire. The fixation component is placed into the metatarsal head under visual controls and three-dimensional mapping of the metatarsal head determines the surface geometry of the joint.

A surface reamer that stops on the fixation component prepares the implant bed. An offset matching sizing trial is placed to confirm the fit to the surrounding joint surface. The final articular component is seated onto the fixation screw by morse taper interlock.

Aside from pain, advanced stages of Hallux Rigidus present themselves with severe loss of motion in the metatarso-phalangeal joint. Several surgical steps have been identified over the course of the past 5 years that are crucial to maximize the clinical benefit of the procedure (Table 1). Joint space narrowing, soft tissue adhesions, bony proliferation, and

aggressive movement promoting rehabilitation have to be addressed concurrently. During the surgical approach, capsular and collateral ligament contractures are released, sesamoid adhesions are mobilized using a McGlamory elevator, and the flexor Hallucis Brevis tendon is often released periosteally at the broad insertion at the base of the proximal phalanx. Addressing the brevis tendon, especially in patients who cannot achieve 90° of dorsiflexion intraoperatively, has shown to provide remarkable benefits to postoperative range of motion without causing instability. The joint line and center of rotation can be moved proximally by advancing the fixation screw 1-3mm deeper into the metatarsal head thus re-creating joint space for the MPJ. Peri-prosthetic osteophytes are removed using the sizing trial as a guide. A phalangeal cheilectomy (12) increases the dorsal space of the MPJ. Depending on the disease stage, using the highest offset curvature for articular resurfacing further improves dorsal roll-back. Phalangeal degeneration can be addressed with adjuvant interpositional grafting using capsular tissue or commercially available substitutes (12,13). It is important to use bioabsorbable anchor fixation to avoid the potential of metallosis caused by possible metal anchor loosening.

Table 1: Technical Pearls and Rehabilitation

- Joint Decompression:
 - o Move MTP joint line back 1-3mm
- Soft Tissue Mobilization
 - o Capsule, collateral ligaments, sesamoids
- Flexor Hallucis Brevis Tendon Release
 - o Subperiosteal release at the bony insertion on the proximal phalanx
- Bioabsorbable Anchors
 - o E.g. fixation of adjuvant interpositional grafting
- Accelerated Rehabilitation
 - o Early range of motion exercises and weight bearing

Accelerated postoperative care is carried out with full weight bearing immediately after the procedure to prevent joint stiffness and maximize the postoperative gain in range of motion.

Clinical Results

Hasselmann and Shields (12, 14) reported the results of the first series of patients using a consistent surgical technique. After a mean follow-up of 20 months, 25 patients with a mean age of 51 showed a post-operative increase in range of motion of the joint of 42 degrees. The mean AOFAS score was 82.1 and SF-36 was 96.1. All patients reported that they were satisfied with the results and would have the surgery again.

At the 5 year follow-up mark (15) Hasselmann et al. contacted their initial patient series of 30 implants (26 patients, 4 bilateral) using a questionnaire (follow-up range 50 to 70 months) to assess current symptoms and satisfaction. All patients responded and continued to report

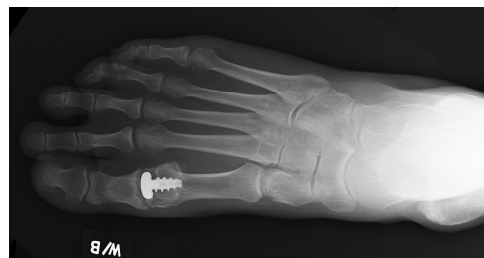

Figure 2: 5 year follow-up radiograph after metatarsal head resurfacing (HemiCAP® Toe I)

excellent satisfaction describing their current state as same or better when compared to their two year follow-up. All said again they would repeat the procedure. The average AOFAS activity rating was 8/10 with no limitations during activities of daily living (Figure 3 a,b). No patient indicated “limited daily” or “severe limitations of daily and recreational activities. The implant survivorship was 88% at 5 years. 4/30 implants, including one bilateral patient were revised using a silastic implant (n=3), one was converted to a primary arthrodesis without the use of interpositional bone graft. All four conversions were indicated due to phalangeal pathology and were performed at the three year mark. All metatarsal head implants were well incorporated without any signs of loosening. Interestingly, all three conversion patients indicated they would repeat resurfacing again as a primary procedure.

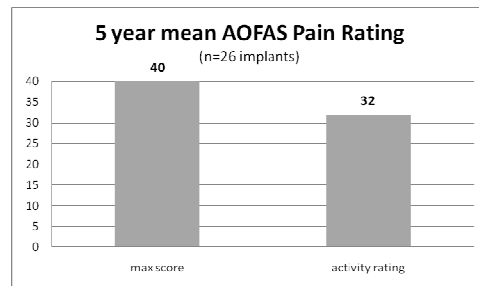
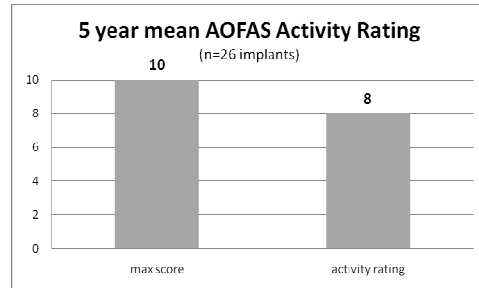


Figure 3 a,b: Activity and Pain Rating at 5 year follow-up in 26 metatarso-phalangeal resurfacing implants

SanGiovanni et al. (16) reported good to excellent results in 76% in 36 patients with 45 months follow-up and an 80% satisfaction rate. Radiographic assessment of a larger cohort of 56 patients demonstrated no significant evidence of loosening. The authors concluded that the implant appeared to show superior radiographic results compared to those of other metallic implants using a stemmed design.

In 2010, Carpenter et al. (17) reported mid-term (27.3 months) results of a series of 30 patients (32 procedures) with an average age of 62.8 years (range 39-86) who underwent implantation with the HemiCAP[®] device for grade II and grade III Hallux Rigidus. The mean change from baseline for the AOFAS score was 236.8%. All patients were satisfied with their results and would have the procedure again if necessary. They concluded that after conservative measures have failed, this procedure achieved excellent mid-term outcomes, while preserving the joint for range of motion.

Second Evolution of HemiCAP[®] MTP Resurfacing

Shereff et al. (18) described MPJ Kinematics showing multiple anatomic centers of rotation throughout the entire range of motion arc on the metatarsal head. In order to further improve dorsal roll back, the second evolution of HemiCAP[®] metatarsal head resurfacing was recently introduced (Figure 4 a,b).

The new implant design incorporates complete dorsal coverage to prevent dorsal impingement with weight bearing and to support range of motion, particularly during full dorsi-flexion. Implant curvatures create a widened joint space dorsally thereby increasing

dorsiflexion. The stability at zero degrees is maintained. Joint decompression is built into the system by the unique dorsal arc respecting first MTP kinematics. The fixation is based on proven concepts studied in the earlier implant design. Preservation of the sesamoid mechanism continues to be maintained. The thin implant profile and shallow inlay bone bed allow for a clinical exit strategy to primary arthrodesis without bone grafting if needed in the future.

Discussion

Many patients today are eager to maintain an active lifestyle for personal or professional reasons and when confronted with treatment options for advanced stages of Hallux Rigidus they reject surgical management using arthrodesis. Patient education is critical as terms like “fusion”, or “arthrodesis” oftentimes are not well understood and result in postoperative surprise when their joint is “permanently stiff”.

When forming a treatment plan, many factors need to be considered such as activity level, stage of the disease, age, expectations, post-operative recovery period and the immediate and long-term requirements. Non-surgical options can be attempted to help alleviate the symptoms. The use of a stiff-soled shoe with extra width to accommodate the enlarged joint can be used to limit the motion of the big toe (19). Adding a rocker-bottom to the sole of the shoe may alleviate the pain by diminishing the movement of the arthritic joint (19,20). Anti-inflammatory medication can help decrease the pain and swelling as well activity restriction, cortisone injection or physical therapy may be helpful in early stages (20).

Hattrup and Johnson reported on a series of patients treated with cheilectomy and concluded that while it is a simple procedure with a low complication rate, satisfactory results were obtained only in patients with Grade I Hallux Rigidus (21). Nawoczinski et al. (22) suggested that although cheilectomy restores some joint motion, the patient’s gait continues to be altered which further contributes to degeneration of the joint. The preoperative planning should include surgical alternatives to cheilectomy because baseline radiographs oftentimes underestimate the amount of cartilage damage to the metatarsal head.

Historically, many attempts were made to preserve joint mobility by using various methods of removing wedges of bone, shortening the metatarsal head or combinations of these procedures (20) Only average results were achieved.

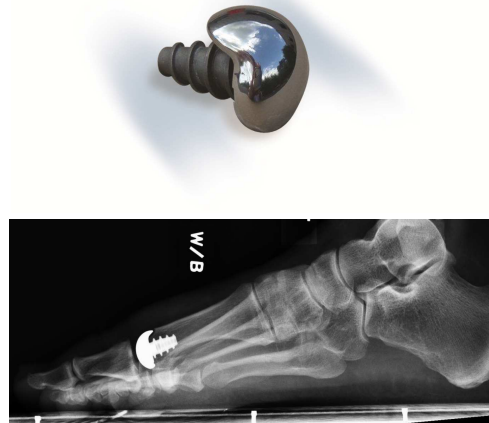


Figure 4 a,b: Second Evolution of HemiCAP[®] Metatarsal Head Resurfacing:

- High pitched, threaded fixation
- Modular Articular Components with various surface curvature offset sizes
- Improved joint kinematics and dorsal roll-back through multiple anatomic centers of rotation incorporated over the full range of motion arc

Raikin et al. (23) reported retrospectively on patients who either underwent phalangeal hemiarthroplasty (average follow-up: 80 months) or arthrodesis (average follow-up: 30 months). They concluded that arthrodesis shows superior results, however the difference in the follow-up times may have influenced these results. They also noted a very high failure rate of 24% in the hemiarthroplasty group and an 18.5% fair or poor result in patients in the arthrodesis group. Despite these short term fair results, fusion of the joint is an end stage procedure that has been associated with many complications by other authors (24-26) including non-union, progressive degeneration of adjoining joints, restrictions in shoe wear, hardware and an extended post-operative recovery time.

Clinical and radiographic results of the HemiCAP[®] metatarsal head resurfacing system have been encouraging in patients with 2 to 5 years follow-up. Particularly patient satisfaction is rated high combined with promising pain relief and functional improvement. The procedure allows for preservation of joint mobility in advanced stages of Hallux Rigidus and is an attractive alternative to arthrodesis which continues to provide a sound clinical exit strategy as a salvage procedure.

The second evolution of implant design has promising concept features. An ongoing prospective multicenter investigation is currently underway to determine if design improvements can be translated into further clinical benefits.

References

1. Brage ME, Ball ST. Surgical options for salvage of endstage hallux rigidus. *Foot Ankle Clin North Am.* 2002;7:49-73.
2. Giza E, Sullivan MR. First metatarsophalangeal hemiarthroplasty for grade III and IV hallux rigidus. *Tech Foot Ankle Surg.* 2005; 4:10-7.
3. Townley CO, Taranow WS. A metallic hemiarthroplasty resurfacing prosthesis for the hallux metatarsophalangeal joint. *Foot Ankle Int.* 1994;15:575-80.
4. Fuhrmann RA. MTP prosthesis (ReflexionTM) for hallux rigidus. *Tech Foot Ankle Surg.* 2005; 4:2-9
5. Johnson KA, Buck PG. Total replacement arthroplasty of the first metatarsophalangeal joint. *Foot Ankle.* 1981; 1:307-14.
6. Cook E, Cook J, Rosenblum B, Landsman A, Giurini J, Basile P. Meta-analysis of first metatarsophalangeal joint implant arthroplasty. *J Foot Ankle Surg.* 2009 Mar-Apr;48(2):180-90.
7. Notni A, Fährmann M, Fuhrmann RAZ [Early results of implantation of an unconstrained metatarsophalangeal joint prosthesis of the first toe]. *Orthop Ihre Grenzgeb.* 2001 Jul-Aug;139(4):326-31.
8. Ronconi P, Martinelli N, Cancilleri F, Marinozzi A, Marineo G, Denaro V. Hemiarthroplasty and distal oblique first metatarsal osteotomy for hallux rigidus. *Foot Ankle Int* 2011 32(2):148-52.
9. Chee YH, Clement N, Ahmed I, Thomson CE, Gibson JN. Functional outcomes following ceramic total joint replacement for hallux rigidus. *Journal of Foot & Ankle Surgery.* 2011;17(1):8-12.

10. Fuhrmann RA, Wagner A, Anders JO. First metatarsophalangeal joint replacement: the method of choice for end-stage hallux rigidus? *Foot & Ankle Clinics*. 2003, 8(4):711-21.
11. Hasselman CT. Hemiarthroplasty of the arthritic first metatarsophalangeal head with a contoured articular prosthesis. Presented at the AOFAS meeting. Toronto, CA 2007.
12. Hasselman CT, Shields N. Resurfacing of the first metatarsal head in the treatment of hallux rigidus. *Tech Foot Ankle Surg*. 2008; 7: 31-40.
13. Berlet GC, Hyer CF, Lee TH, Philbin TM, Hartman JF, Wright ML. A Soft-Tissue Interpositional Arthroplasty Technique of the First Metatarsophalangeal Joint for the Treatment of Advanced Hallux Rigidus Using a Human Acellular Dermal Regenerative Tissue Matrix. *Techniques in Foot and Ankle Surgery* 5(4):257–265, 2006
14. Hasselman CT. Surgical Treatment of Hallux Rigidus Using a Metatarsal Head Resurfacing Implant: Mid Term Follow-up. BOFAS, Carden Park, England November 2007
15. Hasselman CT, Klein AJ. Resurfacing of the metatarsal head for motion preservation in advanced hallux rigidus: 5 year results. BOFAS, Nottingham, England November 2010
16. San Giovanni TP. Arthroscopic HemiCAP Resurfacing. *Operative Techniques in Orthopaedic Surgery*. Wolters Kluwer Lippincott Williams&Wilkins, 2010, Vol 4, Sec1, 3612-22
17. Carpenter B, Smith J, Motley T, Garrett A. Surgical treatment of hallux rigidus using a metatarsal head resurfacing implant: mid-term follow-up. *J Foot Ankle Surg*. 2010 Jul-Aug;49(4):321-5.
18. Shereff MJ, Bejjani FJ, Kummer FJ. Kinematics of the First Metatarsophalangeal Joint;. *JBJS* 1986; 68-A:392-8.
19. Mann RA. Disorders of the First Metatarsophalangeal Joint. *J AM Acad Orthop Surg* 1995;3:34-43.
20. Grady JF, Axe TM, Zager EJ, Sheldon LA. A retrospective analysis of 772 with Hallux Limitus. *J Am Pod Med Assoc* 2002;92:102- 8.
21. Hattrup SJ, Johnson KA. Subjective results of Hallux Rigidus following treatment with cheilectomy. *Clin Orthop Rel Res* 1988; 226: 182-91
22. Nawoczenski DA, Ketz J, Baumhauer JF. Dynamic kinematic and plantar pressure changes following cheilectomy for hallux rigidus: a mid-term follow-up. *Foot Ankle Int*. 2008;29:265-72.
23. Raikin SM, Ahmad J, Pour AE, Abidi N. Comparison of arthrodesis and metallic hemiarthroplasty of the Hallux Metatarsophalangeal Joint. *J Bone Joint Surg* 2007;89A:1979-85.
24. Brage ME, Ball ST. Surgical options for salvage of end-stage hallux rigidus. *Foot Ankle Clin* 2002;7(1):49–73.
25. Coughlin MJ, Shurnas PS. Hallux rigidus. *J Bone Joint Surg Am*, 2004; 86A(suppl 1, pt 2):119–30.
26. Kelikian AS. Technical considerations in hallux metatarsalphalangeal arthrodesis. *Foot Ankle Clin* 2005; 10(1):167–90