

Evaluation of fibula free flap donor site morbidity[☆]

Alan Garrett, DPM^a, Yadranko Ducic, MD, FRCS(C), FACS^{b,c,*}, Raghu S. Athre, MD^{b,c},
Travis Motley, MS, DPM^a, Brian Carpenter, DPM^a

^aDepartment of Orthopedic Surgery, John Peter Smith Hospital, Fort Worth, TX, USA

^bDivision of Otolaryngology and Facial Plastic Surgery, John Peter Smith Hospital, Fort Worth, TX, USA

^cDepartment of Otolaryngology-Head and Neck Surgery, University of Texas Southwestern Medical Center, Dallas, TX, USA

Received 16 December 2004

Abstract

Objective: To evaluate foot and ankle function in a series of patients undergoing fibula microvascular free tissue transfer.

Study design: A nonrandomized, nonblinded analysis was performed using the ankle-hindfoot scale as well as radiographic analysis to determine donor site morbidity.

Results: Overall, foot ankle function was deemed to be good in this series of patients. Average ankle-hindfoot score was 84.82 of a possible 100 (range, 55–100). Radiographic analysis of donor and contralateral ankles showed no difference in the syndesmotomic space or medial clear space. Only 1 patient had increased talar tilt compared with the contralateral side, although this patient had preservation of stability.

Conclusion: Fibula free flap harvest appears to be associated with acceptable donor site morbidity and preservation of good foot and ankle function in most individuals.

© 2006 Elsevier Inc. All rights reserved.

1. Introduction

Continuity defects of the mandible may arise as sequelae of trauma, neoplasm, or congenital deformity. Such defects, if left untreated, often result in significant morbidity including loss of chin/lip support, sensory disturbance, malocclusion, retrognathia, oral incompetence, and difficulties with mastication and speech. Free tissue transfer has revolutionized the reconstruction of large defects of the mandible, especially in the radiated patient population. Although a number of donor sites are available, the workhorse of mandibular reconstruction has been the fibula.

Fibula free tissue transfer has been used successfully in large numbers of patients undergoing microvascular bony reconstruction [1–5]. Taylor et al [4] performed the first 2 free microvascular fibula transfers on human patients to reconstruct tibial bone gaps. Hidalgo [5] reported its

successful use in a large series of patients undergoing reconstruction after extirpative tumor resections. The fibula free flap affords many advantages: consistent vascular anatomy, relative ease of harvest, significant bone stock allowing condyle to condyle restoration if this is required, low donor site morbidity, numerous periosteal and endosteal blood supplies that allows multiple osteotomies, and the ability to accept dental implants [6].

The anatomy of this flap has been well defined. The fibula lying lateral to the tibia is connected to it via the interosseous membrane. Proximally, it articulates with the tibia at the lateral condyle of the tibia, and distally with the talus at the lateral malleolus. The peroneal nerve passes around the neck of the fibula just distal to the head of the fibula. The anterior intermuscular septum separates the anterior and lateral compartments of the leg, whereas the posterior intermuscular septum separates the lateral and posterior compartments. The fibula free flap based on the peroneal artery and its venae comitantes lies medial to the fibula and posterior to the interosseous membrane [7]. The peroneal artery arises from the tibioperoneal trunk distal to the takeoff of the anterior tibial artery and provides vascular supply to the skin of the lateral leg via musculocutaneous and

[☆] No grants or other assistance were received in preparation of this manuscript.

* Corresponding author. Division of Otolaryngology and Facial Plastic Surgery, John Peter Smith Hospital, 1500 South Main Street, Fort Worth, TX 76104, USA. Tel.: +1 817 927 1172; fax: +1 817 927 1605.

E-mail address: yducic@sbcglobal.net (Y. Ducic).

septocutaneous perforators through the posterior intermuscular septum.

Despite its wide use as a donor site, there has been a paucity of literature focusing on donor site morbidity. Although several authors have recommended preserving the distal 5 to 6 cm of the fibula bone in situ to maintain the stability of the ankle mortise, this has not been evaluated in significant numbers of patients [4,8-14]. Complications that have been reported include donor-site muscle weakness, isolated flexor hallucis longus tendon flexion contracture, multiple claw toe deformity, pain, instability, and sensory deficits [9-14].

The purpose of this article is to evaluate morbidity at the donor site after fibula free tissue transfer by evaluating patient satisfaction using the ankle-hindfoot scale and radiographic analysis. The validity of the ankle-hindfoot scale has been previously validated [15].

2. Methods

2.1. Surgical technique of fibula harvest

We routinely harvest fibula free flaps under pneumatic tourniquet application of 360 mm Hg. Proximal and distal stumps of at least 6 to 7 cm of fibular bone are left in situ to maintain ankle and knee joint stability. The length of the stump will vary according to the length of pedicle that is required. The skin paddle, if an osteomyocutaneous flap is being harvested, is centered over the distal one third of the flap as most cutaneous perforators will arise in the distal half of the lower leg. The long axis of the skin paddle lays one third anterior and two thirds posterior to the intermuscular septum.

The skin paddle is incised circumferentially and elevated in a subfascial plane over the peroneus longus and brevis muscles anteriorly and the soleus and gastrocnemius muscles posteriorly. Dissection is continued until the posterior intermuscular septum is reached. At this point, diligent search is made for septocutaneous perforators passing into the skin paddle. Only one perforator is required, but as many as possible are included in the dissection. If no such perforators are identified, another reconstructive modality is chosen for the cutaneous portion of the defect, and a bone only fibula flap is harvested. We feel that musculocutaneous perforators are not reliable enough in 100% of cases to assure survival of the skin paddle.

The peroneus longus and brevis muscles are freed from the anterolateral aspect of the fibula allowing access to the interosseous membrane, which is next released. Proximal and distal osteotomies are made in the fibula and the pedicle controlled distally. The pedicle is then traced proximally to its origin. Once flap harvest has been completed, closure of the leg is accomplished by careful muscle reapproximation and split thickness skin graft application to the donor site if a cutaneous paddle has been harvested. A posterior splint is applied for 5 days at which point in time full-weight bearing with physiotherapy is instituted.

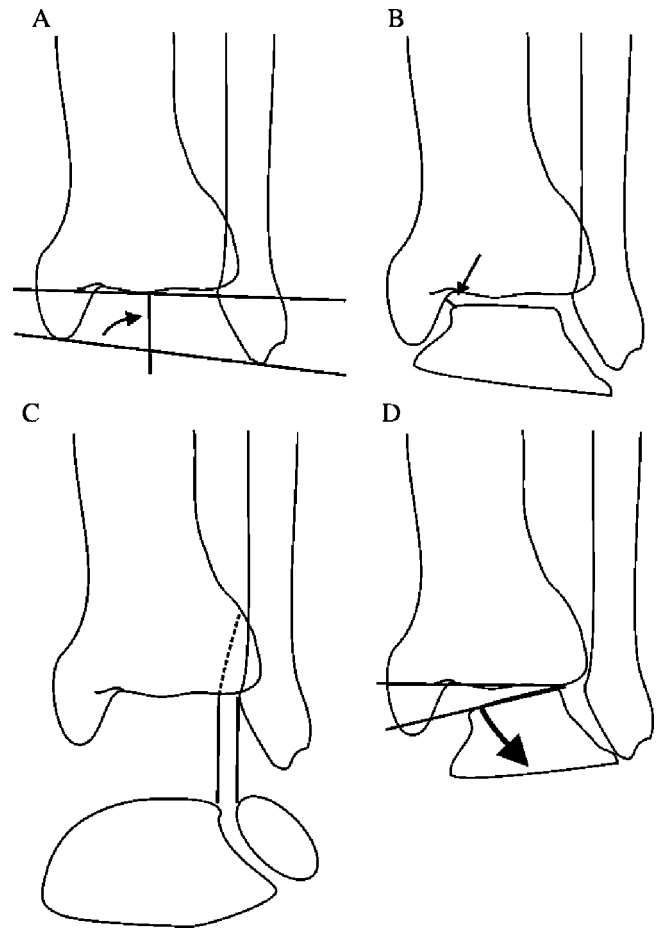


Fig. 1. (A) Talocrural angle. (B) Medial clear space. (C) Syndesmosis. (D) Talar tilt.

2.2. Data collection

A total of 14 patients that had undergone free fibular graft harvest were able to be contacted, willing to participate, and thus included in the study. These 14 represented a small portion of all the fibula free tissue transfers performed by the senior author (YD) from 1997 to 2003, but the constraints of the County Hospital System precluded inclusion of more patients in this study. Available patients were scored using the ankle-hindfoot scale. Information was also recorded with regard to time since surgery, age, height, weight, and donor site. Patients then underwent weight-bearing anteroposterior, oblique, and lateral views of both the donor and contralateral ankle. Measurements evaluated were talocrural angle, medial clear space, syndesmosis, and talar tilt of both ankles (Fig. 1A-D). Length to osteotomy was also measured from the distal tip of the fibula.

3. Results

The ankle-hindfoot scale evaluates ankle, subtalar, talonavicular, and calcaneocuboid joint levels. A score of

Table 1

Patient	Surgery date	Age	Height (ft, in)	Weight (lb)	Donor site	Ankle- hindfoot score
VM	2002	55	5, 5	115	R	74
DW	4/2001	66	5, 6	172	L	100
BR	3/2001	68	5, 7	117	L	99
JM	2/2001	73	5, 0	155	R	97
CW	1999	48	6, 1	165	L	82
MT	2/1999	33	5, 0	150	R	100
JR	9/1997	73	5, 1	172	R	73
RR	1993	66	5, 8	130	L	75
MP	3/1998	79	5, 5	110	L	96
JJ	12/1999	64	5, 8	140	L	55
OB	4/2002	77	4, 11	100	R	82
LS	9/2003	61	5, 9	265	R	100
HY	8/2003	70	5, 11	162	L	87
LS	9/2003	61	5, 9	265	R	100

100 points is possible in a patient with no pain, full range of motion in the sagittal and frontal planes, no ankle or hindfoot instability, good alignment, and ability to ambulate more than 6 blocks without limitations or need for supportive device. A score greater than 80 is within the range considered to be normally functional. Fourteen patients were evaluated using this scale and had the following results. Eight patients reported no pain in the donor ankle, whereas 5 reported mild or occasional pain. Only 1 patient reported moderate daily pain, but reported that their pain was due primarily to their underlying peripheral vascular disease. Overall, 3 of the 6 patients reporting pain at the ankle stated that it was not significantly changed from preoperative or different from the contralateral nonoperated side. The remaining 3 patients (all reporting mild pain) did not have contralateral ankle pain. In regard to ankle function, 9 patients reported no limitations to daily activities in normal shoe gear. Four reported having some limitation of daily activities, whereas 1 reported having limitation of daily activity requiring a cane for ambulation. Seven patients were able to ambulate more than 6 blocks with no difficulty after recovery from the procedure. One was able to ambulate 4 to 6 blocks, whereas 6 were only able to ambulate 1 to 3 blocks without rest. Patients with limitations on walking distance reported underlying medical conditions including congestive heart failure, chronic back, knee, or hip pain, or other pulmonary pathology. Those with limitations on walking distance had no significant change in their distance as compared with preoperative distance.

Stability on various walking surfaces was also evaluated. Eight patients had no difficulty with stability on any surface. Six reported some difficulty on uneven terrain, stairs, or inclines. All 14 patients denied having any obvious gait abnormality. Eleven patients had no sagittal motion restriction having at least 30° of flexion and extension of the ankle. Two had moderate restriction in the sagittal plane with only 15° to 29° of motion at the ankle. One patient had stiffness at the ankle with less than 15° of flexion or extension at the ankle joint.

Evaluation of the hindfoot had similar results with the same breakdown of normal, moderate, and marked

restriction of hindfoot motion. All patients had a stable foot and ankle for ambulation. Alignment was evaluated for the presence of a plantigrade foot and if the ankle-hindfoot was well aligned in neutral position. Ankle-hindfoot scores are shown in Table 1. The average score for the patients evaluated was 84.82 of 100, with a range of 55 to 100. Radiographic evaluation of donor and contralateral ankles showed there was no difference in syndesmotoc space or medial clear space. Only 1 patient had an increase in the talar tilt angle compared with the contralateral side.

No other donor-site complications were noted in this group of patients. Patients in the study group all had 8 to 10 cm of distal fibula preserved.

4. Discussion

Previous studies have recommended preserving at least 5 to 6 cm of the distal fibula to maintain ankle mortise stability [4,8]. All procedures reviewed radiographically in this study had an osteotomy that preserved greater than 8 cm of the distal fibula.

Functionally, low morbidity was noted with 13 of 14 patients surveyed having only mild or no pain at the donor ankle site. In addition, 9 of 14 patients had no limitation of function without any support needed, and 4 of 14 had some limitation of function, but were able to perform daily activities. All 14 patients evaluated had no gait abnormality and a stable ankle and hindfoot. Of 14 patients, 13 (93%) also reported having at most a mild restriction in the sagittal and frontal planes of the ankle and hindfoot, respectively. These data would suggest low donor site morbidity to the affected ankle.

Structurally, it appears that overall stability and function are maintained at the donor ankle with this reconstructive procedure. One patient (CW) had an increased talar tilt compared with the donor ankle. Although this measurement is indicative of some ankle instability, the same patient had an ankle-hindfoot score of 82, suggesting that function was only minimally impaired. In our study, talocrural angles did not correlate to patient scores on the ankle-hindfoot scale. This is an interesting finding because the fibula has been

shown to function as a lateral strut to the talus and play an important role in maintaining the articular surface of the talus on the tibia [16]. The ankle syndesmosis likely has enough strength to prevent larger than normal excursion of the fibula and maintain the lateral gutter of the ankle joint if enough distal fibula is left after harvest. Because most muscles in the deep posterior muscle group originate proximal to the fibular osteotomy site, their addition to ankle stability is not disrupted with this procedure. In addition, the function of these muscles is not altered, thus allowing for normal function during gait.

Although this study represents a small sample size, these results are promising concerning patient ankle function and stability after free fibular grafts. Results from this study using the ankle-hindfoot scale and follow-up radiographs support a low morbidity rate at the donor site after free fibula graft harvest.

References

- [1] Ueba Y, Fujikawa S. Nine years follow up of a free vascularized fibular graft in neurofibromatosis—a case report and literature review. *Jpn J Orthop Trauma Surg* 1983;26:595-600.
- [2] Horiuchi K, Hattori A, Inada I, et al. Mandibular reconstruction using the double barrel fibular graft. *Microsurgery* 1995;16:450-4.
- [3] Weber RA, Pederson WC. Skin paddle salvage in the fibula osteocutaneous free flap with secondary skin paddle vascular anastomosis. *J Reconstr Microsurg* 1995;11:239-41.
- [4] Taylor GI, Miller GD, Ham FJ. The free vascularized bone graft. A clinical extension of microvascular techniques. *Plast Reconstr Surg* 1975;55:533-44.
- [5] Hidalgo DA. Fibula free flap: a new method of mandible reconstruction. *Plast Reconstr Surg* 1989;84:71-9.
- [6] Chen ZW, Yan W. The study and clinical application of the osteocutaneous flap of fibula. *Microsurgery* 1983;4:11-6.
- [7] Disa JJ, Cordeiro PG. Mandible reconstruction with microvascular surgery. *Semin Surg Oncol* 2000;19:226-34.
- [8] Weiland AJ, Moore JR, Daniel RK. Vascularized bone autografts. Experience with 41 cases. *Clin Orthop* 1983;174:87-95.
- [9] Vail TP, Urbanlak JR. Donor-site morbidity with use of vascularized autogenous fibular grafts. *J Bone Joint Surg Am* 1996;78:204-11.
- [10] Anthony JP, Rawnsley JD, Benhalm P, et al. Donor leg morbidity and function after fibula free flap mandible reconstruction. *Plast Reconstr Surg* 1995;96:146-52.
- [11] Babhulker SS, Pande KC, Babhulker S. Ankle instability after fibular resection. *J Bone Joint Surg Br* 1995;77:258-61.
- [12] Ganel A, Yaffè B. Ankle instability of the donor site following removal of vascularized fibula bone graft. *Ann Plast Surg* 1990;24:7-9.
- [13] Gore DR, Gardner GM, Sepic SB, et al. Function following partial fibulectomy. *Clin Orthop* 1987;220:206-10.
- [14] Shpitzer T, Nellgan P, Boyd B, et al. Leg morbidity and function following fibular free flap harvest. *Ann Plast Surg* 1997;38:460-4.
- [15] Kitaoka MD, Alexander MD, Adelaar MD, et al. Clinical rating systems for the ankle-hindfoot, midfoot, hallux, and lesser toes. *Foot Ankle Int* 1994;15:349-53.
- [16] Yablon IG, Heller FG, Shouse L. The key role of the lateral malleolus in displaced fractures of the ankle. *J Bone Joint Surg* 1977;59(2):169-73.